



"Terminal ileopathy" – a common malabsorptive syndrome developing after irradiation treatment for pelvic malignancy and after ileal resection.

Hultén L & Delaini GG*

Department of Surgery . The Colorectal Unit
Sahlgrenska University Hospital/ Göteborg SWEDEN
*Chirurgia C Policlinico, Verona

Abstract

Patients having had an ileal resection or a significant segment of ileum excluded and used for construction of a continent urinary diversion as well as those in whom radiation treatment of gynaecological, bladder or -rectal cancer have injured distal small bowel - all these patients will develop a characteristic malabsorption syndrome, a "terminal ileopathy" Patients often suffer a troublesome and socially inconvenient watery diarrhoea. Apart from vitamine B₁₂-malabsorption - which untreated may give rise to megaloblastic anaemia and irreversible neurogenic disturbances - the bile salt malabsorption causes a series of

other events, the severity of which varies with the magnitude of malabsorption.. The condition called "terminal ileopathy" includes a number of malfunctions, such as watery diarrhoea, steatorrhea, hyperoxaluria, malabsorption of fat soluble vitamins and minerals. Stoma - and urotherapists are those who have a more intimate contact with these patients in the postoperative phase. Their understanding of the malabsorptive syndrome and the underlying pathophysiological mechanism is therefore of special importance and also a prerequisite to a successful management.

Keywords: Ileal resection.Malabsorption.Radiation damage.

Introduction

The rectum is the most common part of the gastrointestinal tract to be involved in complications after pelvic radiation therapy.

When the pelvis is irradiated for malignancy in patients with gynecologic, urologic, and rectal cancer not only the rectum but even distal parts of the small bowel - particularly the ileum - is at risk for radiation injury because of their position and proximity to the treated organs.

Radiation of the rectum leads to an ischemic injury with bleeding,rectal pain, passage of mucus, incontinence, and tenesmus. being the most common symptom while bleeding, ulcers, fistulas, and stricturing may develop at a later stage.

To date, many treatments such as aminosalicylic acid,steroid enema, sulfasalazine, formalin etc., have been tried with varying results.(1)

However apart from the rectal injury and associated symptoms these patients also suffer from socially inconvenient imperious watery diarrhoea.

In contrast to the literature for radiation proctitis, there is a paucity of knowledge about the underlying mechanisms and proper management of this diarrhoea (2). However, the symptoms are similar to those in patients with Crohn's disease of the terminal ileum and the morphological features in the small bowel wall are also similar with submucosal oedema, progressive submucosal fibrosis shortening of villi and a characteristic irradiation vasculitis. (3) In patients with classical Crohn's disease - particularly after ileal resection - this condition has become a clearly defined malabsorptive syndrome often referred to as "terminal ileopathy".(fig 1)

Fig 1 The malabsorption pattern in "Terminal ileopathy".

"TERMINAL ILEOPATHY"

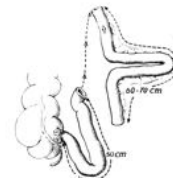
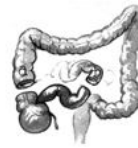- Vitamin B₁₂ -malabsorption
- Bile salt malabsorption
- Watery diarrhoea
- Steatorrhoea
- Hyperoxaluria
- Malabsorption of vitamins A,D,E,and K
and minerals (Mg⁺⁺,Zn⁺⁺,Ca⁺⁺)

Patients who have had radiation treatment for rectal, bladder, or gynecological cancer will - apart from the rectal injuries - may develop the (25-26);

same characteristic malabsorption syndrome due to radiation damage to the distal small bowel (fig 2)(8, 12, 13, 27).

Fig 2. "Terminal ileopathy" - common causes

- Ileal disease/resection
- Ileal utilization/Uro-diversion
- Radiation injury



(Gynecol.cancer,bladder cancer
rectal cancer)

Pathophysiological mechanisms

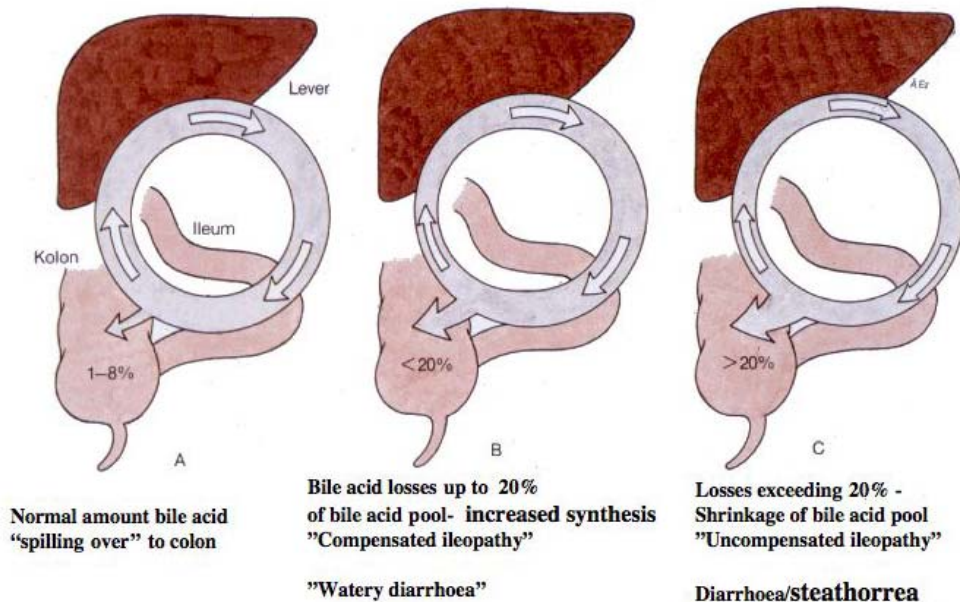
Specific receptors for absorption of vitamin B₁₂ and bile acids are located in the terminal ileum. Apart from vitamin B₁₂ - malabsorption - which untreated may give rise to megaloblastic anaemia and irreversible neurogenic disturbances - the syndrome includes a number of other malfunctions, most of them secondary to bile salt malabsorption.

Normally less than 10 per cent of bile acids escape reabsorption and spill over in the colon (fig 3 A,B,C).

Due to interruption of the enterohepatic circulation increasing amounts of bile acids enter the colon (5, 10, 18).

Fig 3 The magnitude of bile acid malabsorption related to the severity of ileal resection /dysfunction..

- A.** Bile acid "spill over" to colon normally 1-8 %.
B. Liver compensate bile acid losses up to 20% by increased synthesis.
C. Liver unable to compensate losses exceeding 20% -the total bile acid pool decrease and steatorrhea develops.



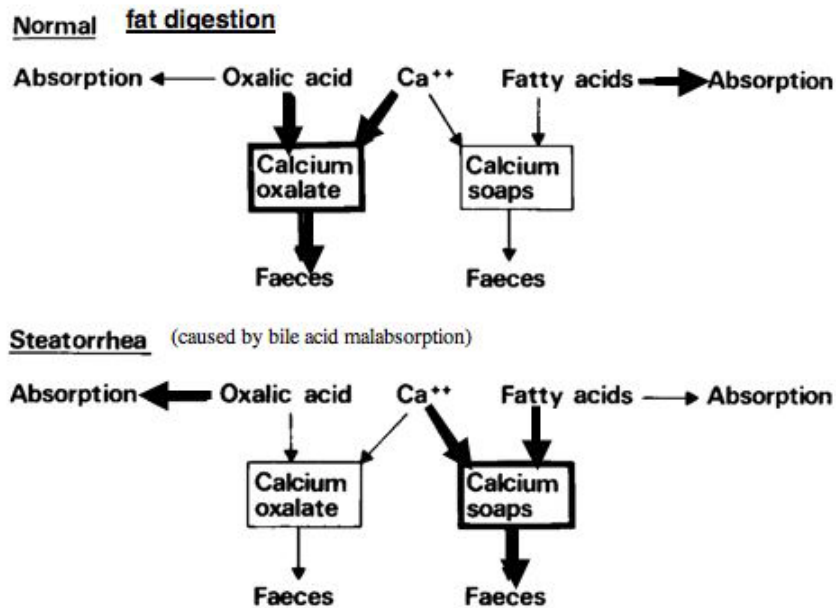
Even moderate amounts of bile acids spilling over into the colon interfere with water and electrolyte absorption and increase mucosal secretion and colonic motility (19, 22) - The resulting diarrhoea - socially inconvenient sometimes incapacitating - is characteristically watery and urgent occurring mostly in the morning or after breakfast. In patients with only minor or moderate ileal dysfunction (less than 20 per cent spill over of bile acids) an increased liver synthesis will compensate for the bile salt losses. Bile acid concentration in duodenal bile is kept normal and fat digestion will remain unaffected. In patients with more extensive malabsorption however (bile acid losses exceeding 20 per cent) the liver may be unable to compensate for these losses. The duodenal bile salt concentration will decrease below the critical level for micellar formation, fat digestion will be incomplete with increasing amounts of free fatty acids (steatorrhea) spilling over into colon aggravating the diarrhoea (6, 11).

In this latter situation the resulting fat malabsorption will in turn interfere with the oxalate metabolism (9-10). According to "the solubility theory" most fatty acids are under ordinary conditions absorbed, only small amounts escaping in faeces as insoluble calcium soaps (7). For example oxalic acid in the food (tea, spinach, chocolate etc) is effectively taken care of by calcium forming insoluble oxalate which is expelled with the faeces. Under normal conditions only small amounts of oxalic acid are therefore absorbed from the intestine fig 4 (upper panel).

However in patients with steatorrhea the formation of insoluble calcium soaps interfere with this mechanism. Increasing amounts of oxalic acid will be absorbed, and the concentration of oxalic acid in urine will increase (fig 4, lower panel). Patients with hyperoxaluria are at risk for developing urinary calculi (16).

Fig 4: Hyperoxaluria - the "solubility theory".

Normally, only small amounts of fatty acids escaping in faeces as insoluble calcium soaps (upper panel). Steatorrhea results in the formation of large amounts of insoluble calcium soaps and increasing amounts of oxalic acid will be absorbed, (lower panel).



In patients with steatorrhea; the defect micellar formation may also interfere with absorption of fat soluble vitamins (A,D,E and K) and divalent cations such as calcium and magnesium may form subcomplexes with

malabsorbed fats, which may cause mineral deficiencies.

The changes in the enterohepatic circulation may also favour the development of gall stones.

A reduced bile acid concentration favours precipitation of cholesterol (15, 17).

Management

Impairment of vitamin B12 -absorption and absorption of fat soluble vitamins A,D,E and K is the simplest problem with which to deal. Vitamin B12- either by intramuscular injection or supplied orally should be administered regularly in these patients.

The best way by which the diarrhoea should be managed is controversial however and partly or entirely depending on the severity of the malabsorption. Important experience has been gained from patients with Crohn's disease in whom varying length of distal small bowel has been resected (21). Codeine phosphate or loperamide, both exerting their effect mainly by slowing intestinal transit, may be effective in controlling the watery - bile acid induced - diarrhoea developing after limited ileal resections (30-50 cm) but are often insufficient when steatorrhea has developed. Cholestyramine - a bile acid binding resin- may also be useful in patients who have only a mild or moderate

disturbance of bile salt malabsorption (20, 23). When more pronounced and in those who have developed fat malabsorption, however, cholestyramine will rather aggravate the diarrhoea and should therefore be avoided. Moreover, apart from interference with absorption of fat and fat soluble vitamins - the side effects of this unpalatable drug - nausea, vomiting, abdominal cramps - also limit its use. Thus, in most patients who have a more pronounced malabsorption, both motility-retarding drugs and cholestyramine have proven insufficient to cure the diarrhoea.

MCT (Medium Chain Triglycerides (MCT) has often been used to patients with malabsorption as this fat can hydrolyze and be absorbed without previous emulsification.

Although encouraging results may be obtained but bad tolerance and side effects have limited the use of MCT.

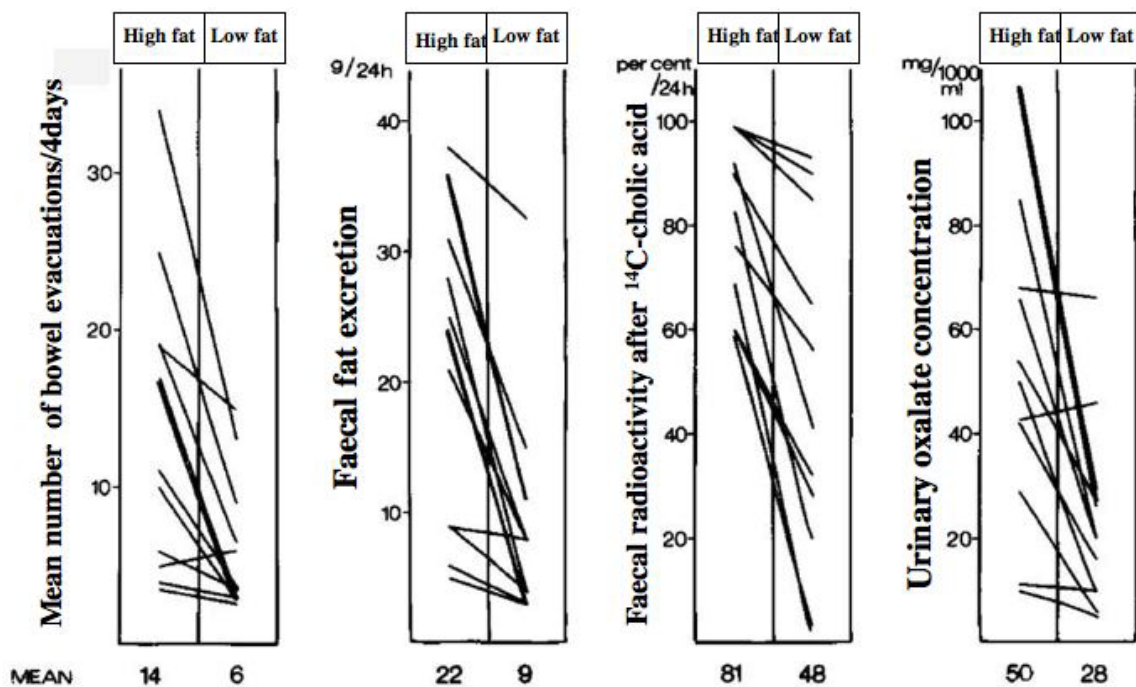
Low fat diet

The beneficial effect of a low-fat diet which was first noted by Booth et al (4). Has been convincingly demonstrated subsequently by means of careful studies done under "metabolic ward" conditions both on patients after surgery for Crohn's disease and patients after irradiation for pelvic malignancies, (8, 12, 14). The majority of patients - even those with an extensive loss or

damage of distal small bowel - may get a satisfactory or good bowel function by adhering strictly to a fat reduced diet, (21, 24)

By sparing bile salts a low fat diet decreases faecal water reducing evacuation urgency and frequency, decreases faecal fat and reduces hyperoxaluria. The marked effects of low fat diet are reflected in fig 5.

Fig 5 . No of bowel evacuations, faecal fat ,bile salt excretion and urinary oxalate concentration before and after low fat diet.



Restoration of the solubility of bile decreases the risk for gallstones. Hyperoxaluria is promptly and effectively decreased preventing the development of urinary calculi.

To obtain these beneficial effects, however, the daily fat contents in food must be considerably reduced (40-50 g). To make a low fat diet effective and still palatable a careful information and regular supervision by a dietician is a must.

It has to be emphasized that patients who have retained the major part of their colon after ileal resection respond the very best to the low fat diet.

It has been observed that cholecystectomized patients seem to respond less well to the treatment.

Conclusion

A clear understanding of the "ileopathy" and the underlying pathophysiological mechanism in patients in whom the terminal ileum has been resected or damaged by radiation is a prerequisite to proper management of the resulting

consequences. The condition can mostly be effectively controlled by simple measures, a low fat diet being the key to success. A close cooperation with dietician is mandatory however.

Referenses

1. Parikh S, Hughe C, Salvat E, Eisensta T, Oliver G, Chinn, B, Notaro J: Treatment of Hemorrhagic Radiation Proctitis. *Dis Colon Rectum* 46:596-600, 2003
2. Mc Gough C, Baldwin C, Frost G, Andreyev HJN: Role of nutritional intervention in patients treated with radiotherapy for pelvic malignancies. *Brit J Cancer* 90; 2278-2287, 2004
3. Brahme F, Lindström C: A comparative radiographic and pathological study of intestinal vaso-architecture in Crohn's disease and ulcerative colitis. *Gut* 11: 928-940, 1970
4. Booth CC, MacIntyre I, Mollin DL: Nutritional problems associated with extensive lesions of the distal small intestine in man. *Quart J Med* 131: 401-406, 1964
5. Hofmann, AF: Bile acid malabsorption caused by ileal resection. *Arch. intern. Med.* 139: 597-605, 1972
6. Ammon HV, Phillips SF: Inhibition of ileal water absorption by intraluminal fatty acids. *J Clin Invest* 53:205 - 210, 1974
7. Andersson H, Jagenburg R: Fat reduced diet in the treatment of hyperoxaluria in patients with ileopathy. *Gut* 15:360 - 366, 1974
8. Bosaeus I, Andersson H and Nyström C: Effect of low fat diet on bile salt excretion - and diarrhoea in the gastrointestinal radiation syndrome. *Acta Radiol Onchol* 18: 460-464, 1979
9. Andersson H, Filipsson S, Hultén L: Determination of the faecal excretion of labelled bile salts after i. v. administration of 14 C-cholic acid. An evaluation of the bile salt malabsorption before and after surgery in patients with Crohn's disease. *Scand J Gastroenterol* 13:249 - 255, 1978 a
10. Andersson H, Filipsson S, Hultén L: Urinary oxalate excretion related to ileocolic surgery in patients with Crohn's disease. *Scand J Gastroenterol* 13:465-469, 1978 b
11. Bright-Asare P, Binder HJ: Stimulation of colonic secretion of water and electrolytes by hydroxy fatty acids. *Gastroenterology* 64:81, 1973
12. Filipsson S, Hultén L, Lindstedt G: Malabsorption of fat and vitamin B 12 before and after intestinal resection for Crohn's disease. *Scand J Gastroenterol* 13:529, 1978
13. Filipsson S: Malnutrition and malabsorption in Crohn's disease. Thesis 1977. Uno Lundgren Tryckeri AB
14. Andersson H, Bosaeus I, Brummer RJ: Fasth S, Hultén L, Magnusson O, Strauss B. Nutritional and metabolic Consequences of extensive bowel resection. *Dig.Dis* 4; 193-202, 1986
15. Heaton KW, Read AE: Gallstones in patients with disorders of the terminal ileum and disturbed bile salt metabolism. *Br Med J* 3:494 -496, 1969
16. Hessov I, Fasth S, Hellberg R, Hultén L: Urolithiasis and urinary oxalate, calcium and magnesium in small bowel resection. Symposium on Clinical Nutrition, London, July 1980
17. Hill GL, Mair WSJ, Goligher JC: Gallstones after ileostomy and ileal resection. *Gut* 16:932-936, 1975
18. Hofmann AF: The syndrome of ileal disease and the broken enterohepatic circulation: Choleric enteropathy. *Gastroenterology* 52:752 -757, 1967
19. Kirwan WO, Smith AN, Mitchell WD et al: Bile acids and colonic motility in the rabbit and the human. *Gut* 16:894, 1975
20. Hofmann, AF and Poley, JR: Cholestyramine treatment of diarrhea associated with ileal resection. *New Engl. J. Med.* 281: 397-402, 1969
21. Hellberg R: The outcome of surgery in Crohn's disease. Thesis, Partille: Lundgrens Tryckeri AB, 1981
22. Mekhjian HS, Phillips SF, Hofmann AF: Colonic secretion of water and electrolytes induced by bile acids. Perfusion studies in men. *J Clin Invest* 50:1569, 1971
23. Sandhu B, Tripp JH, Candy DCA, Harries JT: Loperamide inhibits cholera toxin-induced small intestine secretion. *Lancet* 29:689-690, 1979
24. Andersson H, Bosaeus I, Hellberg R, Hultén L: Bowel habits after resectional surgery for "classical Crohn's disease with special reference to the effect of low fat diet. *Acta Chir Scand* 148:285-290, 1982
25. Kryger-Baggesen N, Moldow B, Rasmussen G, Dissing I, Moller EH, Ladefoged K, Jarnum S: Chronic radiation enteropathy. A retrospective study. *Ugeskr Laeger* 20;155(51):4180-4, 1993 Dec
26. Yeoh E, Horowitz M, Russo A, Muecke T, Robb T, Maddox A, Chatterton B: Effect of pelvic irradiation on gastrointestinal function: a prospective longitudinal study. *Am J Med* 95(4):397-406, 1993 Oct
27. Danielsson A, Nyhlin H, Persson H, Stendahl U, Stenling R, Suhr O: Chronic diarrhoea after radiotherapy for gynaecological cancer: occurrence and aetiology. *Gut* 32(10):1180-7, 1991 Oct