



Pudendal Nerve Compression Syndrome

Bruno Roche, Joan Robert-Yap, Karel Skala, Guillaume Zufferey

Clinic of Proctology
Dept. of Visceral Surgery
HUG, Geneva, Switzerland

Introduction

The pudendal nerve primarily innervates the perineum. This nerve can be gradually stretched and damaged by vaginal deliveries (esp. traumatic births), prolapse of pelvic organs and by pelvic floor descent. This leads to uni- or bilateral pudendal nerve damage. A direct lesion of the pudendal nerve is rare as it lies deep in the pelvis and is well protected by the pelvic ring. It can be injured however, by

pelvic ring fractures, penetrating injuries, and deep hematomas due to injections as well as by bullet and stab wounds. Moreover, it can be damaged by overstretching, for example with repositioning or reduction of fractures on the orthopedic table or by long-continuous stretching due to sitting for prolonged periods, for example, on a bicycle [1].

Anatomical Basis

As the final branch of the pudendal plexus the pudendal nerve is predominantly a somatic nerve, which has its origin in the ventral spinal nerve roots S2-S4 (Fig. 1). It leaves the pelvic floor by the major ischial foramen below the piriformis muscle (infrapiriformis foramen).

After it circles the sciatic spine, the nerve usually gives off a first branch (one of the inferior rectal nerves) (Fig. 2). This branching can also occur higher up on the upper wall of the sacrospinal ligament. As it travels further into the perineum, beyond the lower wall of the sacrospinal ligament, it enters into the pudendal nerve vascular bundle, which continues into the facial layers of the obturator muscle into the Alcock canal. In the Alcock canal the nerve delivers its branches for the perineum and continues into its final branch, the dorsal nerve, which supplies the penis or the clitoris (Fig 2).

The inferior rectal nerve supplies the muscle of the external anal sphincter and the skin in the perianal region. The perineal nerve supplies the sensory component of the perineum: the

scrotum in the man, the labia majora in the woman. It supplies the motor component to the bulbospongiosus, ischiocavernosus, transversus superficialis and profundus perinei muscles as well as the outer striated urethral sphincter. Its final branch is also involved in the sensitivity of the penis or the clitoris.

Possible Compression Sites

In its path, the pudendal nerve can be compressed in different places. The first place is in the upper part of the infrapiriformis foramen, where the inferior gluteal nerve, blood vessels as well as the ischiatic nerve surround the pudendal nerve. This depression can be narrowed by osteophytes of the ischiatic spine or by hypertrophy of the piriformis muscle due to excessive abduction and flexion movements (Fig.3) [2]. The second place is behind the ischiatic spine (Fig. 3). A third conflict zone represents the bottleneck formed by the sacrospinal and sacrotuberal ligaments (Fig. 1) [5, 9, 10, 3]. Over the years, changes in the relationship of these two

ligaments can arise to each other, whereby a rotation of these structures causes a closer superposition [3]. In some cases the nerve breaks through the sacrospinal ligament [4]. Finally the nerve can be compressed also in the Alcock canal, either by contact with the falciform process (Fig. 2) [5,9] or by a thickening of the internal obturator muscle

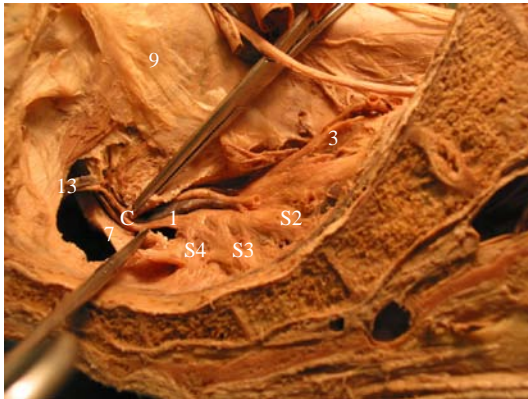


Fig. 1 Medial pelvic view. Origin of the pudendal nerve. The levator ani muscle is partially separated. The two ends of the sacrospinal ligament are supported by clamps. One sees the sacrotuberall ligament (7) and the pudendal nerve (1), which enters the pelvis along this ligament.

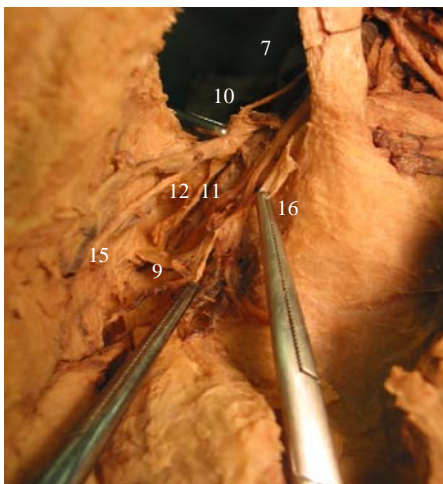


Fig. 2 Posterior view into the ischioanal fossa. Opening of the Alcock canal. The edges are held by clamps. The nerve runs in the canal together with the blood vessels and delivers its branches, which lead into the ischioanal fossa.

fascia [5]. The latter can move cranially during the transition from sitting into the upright position. [2, 6].

Considering the anatomical variability of the path of the nerve, the localization of the pain in the perineal region can be the only clue to localize the area of compression.

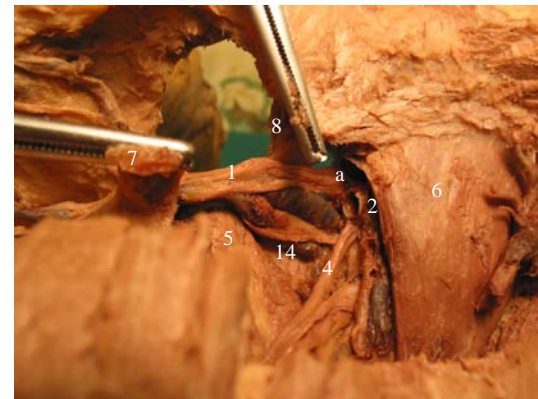


Fig. 3 Posterior view of the gluteal region after opening gluteus max. muscle. Path of the pudendal nerve through the major ischiatic foramen under the piriformis muscle. The sacrotuberall ligament is separated and supported with clamps, in order to expose the nerve, which becomes visible in the place where it circles the ischiatic spines behind the sacrospinal ligament.

Legend : 1. Pudendal nerve, 2. lower Gluteal vessels, 3. Lumbosacral trunk, 4. post. cutaneous femoral nerve 5. Obturator int. muscle and gemelli muscle 6. Piriformis muscle 7. Sacrotuberall ligament 8. Sacrospinal ligament, 9. Obturator int.fascia, 10. Inf.rectal nerve 11. Perineal nerve, 12. Dorsalis penis/ clitoridis nerve, 13. Open levator ani muscle, 14. Ischiatic spine, 15. Ischioanal fossa, 16. Ischiatic tubercle
S1, 2, 3, 4 = Sacral Nerves

Compression sites: a) under Piriformis muscle
b) ischiatic spine c) passage between sacrotuberall ligament and sacrospinal ligament
d) Alcock channel

Symptoms of Pudendal Neuralgia

The damage of the pudendal nerve by compression is comparable to carpal tunnel syndrome or the compression of the nerve in other tunnel syndromes, like the ulnar nerve in the Guyon Loge. The compression affects women more than men in a frequency of 2 to 1. Symptoms are continuous, spontaneous pain in the perineal area supplied by the pudendal nerve. The pain is usually characterized as neuralgia with associated paresthesias as well as occasional electric shocks. The pain is provoked in the sitting position and worse with bicycle riding. [7]. Frequently the patients complain about burning, which accompanies this pain. They are alleviated when standing and walking. Pain in the lying position occurs very rarely, and in general, does not occur at night and therefore does not disturb sleep. Any of the organs supplied by the pudendal nerves can be affected, thus producing pain in the testicle in males, the labia of females, pain in the anus and a foreign body sensation in both sexes. All these symptoms are usually unilateral and can

be an expression of isolated damage of one of the nerve branches.

The clinical examination often shows no disturbance of sensitivity, however in the vaginal or rectal exam, there is a trigger zone in the area of the ischial spines. Pressure on this area releases violent pain, which can spread and reproduce the same pain from which the patient suffers. This is not always the case and all these elements are not specific for neuralgia, they can also result from other pelvic floor disorders such as coccydynia. However, if the history and clinical exam reveals unilateral pain and symptoms, there is high suspicion for pudendal neuralgia. The distal compression of the pudendal nerve must be differentiated from other neurological disease pictures, especially damage higher in the nerve roots or the plexus caused by herpes zoster, radiotherapy, neoplastic infiltration, spinal cord lesions, benign and malignant tumors, in particular neuromas and ependymomas.

Diagnosis

The diagnosis is based on the history, and physical exam as mentioned above. However, electrophysiological investigations, and supplementary investigations such as pelvic x-ray, bone scan, MRI of the pelvis and conus medullaris, and selective infiltration of the pudendal nerve under fluoroscopy, echography or electro stimulation can be helpful.

a) Electrophysiological Diagnosis

The evaluation of the electrophysiological investigation of the perineum is frequently difficult. The existence of a unilateral peripheral nervous lesion can signal a lesion of the main trunk of the pudendal nerve. The sacral nerve latency is of importance only if it is normal: in this case proximal damage higher on the nerve

root can be excluded. Prolonged nerve latency, is not pathognomonic for pudendal nerve compression as this can be the result of surgery damaging the nerve or trauma in the pelvis such as that caused by dystocia during delivery. [2]. The pudendal nerve terminal motor latency PNTML, which is determined by endorectal stimulation with a St.Marks electrode, is unreliable, as it is difficult to interpret and to reproduce. Since pudendal nerve compression occurs more frequently in women, the latency is often high, and only a very clear one-sided change can be an indication of compression. The PNTML measurement for the diagnosis of neurological pelvic floor defects is used far less nowadays.

b) Pelvic X-Ray

A tumor compressing the sacral nerve roots or the pudendal nerve can be excluded by a frontal and lateral x-ray of the pelvis. Such neoplasias are however, extremely rare. Some cases of exostoses of the sciatic spines causing pudendal nerve compression were described [8].

c) Bone scan

A bone scan can be helpful in suspicion of posttraumatic bony lesions or neoplastic growth. The scan must be performed together with a standard x-ray, however nowadays, MRI has often replaced these tests.

d) Pelvic MRI

The MRI can reveal lesions in the pelvic floor, rectal and uterine prolapse as well as presacral tumors, which compress the plexus. Plexus damage and nerve compressions are often not directly revealed by MRI.

e) MRI of the Cone Medullaris

This investigation is essential in the assessment of perineal pain. It can reveal focal anomalies, such as benign or malignant tumors (eg. neurinomas, ependymomas), which can be responsible for perineal pain.

Therapies

a) Infiltration of the Alcock's Canal

The various compression sites of the pudendal nerve can be infiltrated with corticosteroids and long-acting local anesthetics. These infiltrations are accomplished under radiosopic control. Infiltration of the Alcock canal under CT [9] (Fig.4) or ultrasonic control has been recently described. [10]

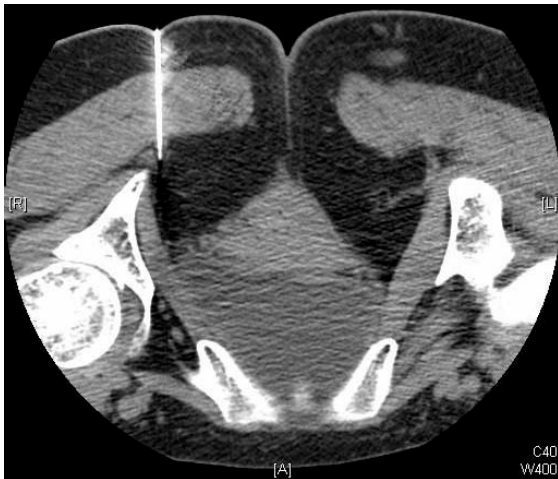
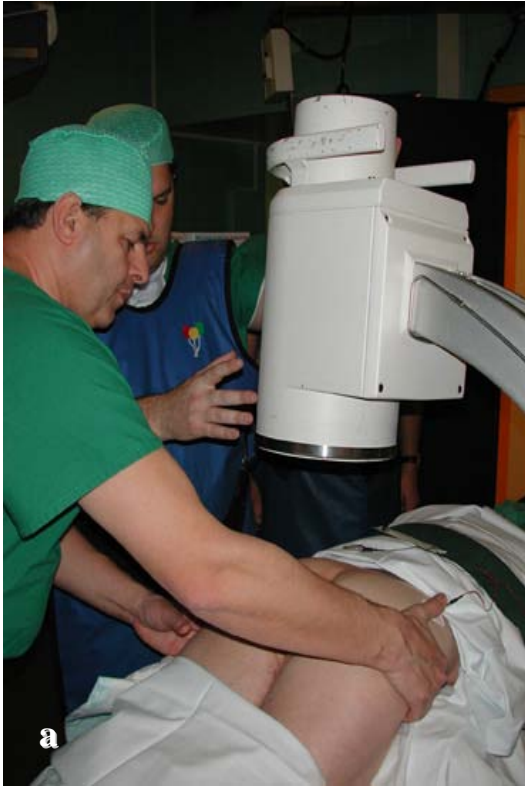
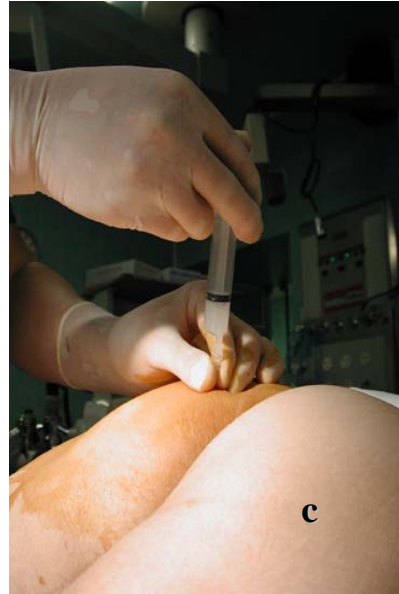Fig. 4 CT-Scan guided infiltration of the pudendal nerve

From January 2000 to February 2008 diagnostic infiltration was performed in 224 patients in our institution. Selective infiltration of the pudendal nerve under fluoroscopy, with electro stimulation was considered as the technique of choice (Fig. 5). [11,12]

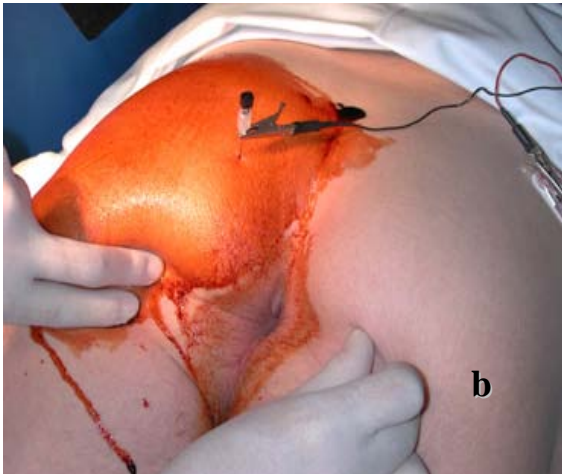
Diminution of the pain occurred in 193 (86.2 %) cases. Infiltration was therapeutic in 53 patients (23.6%).



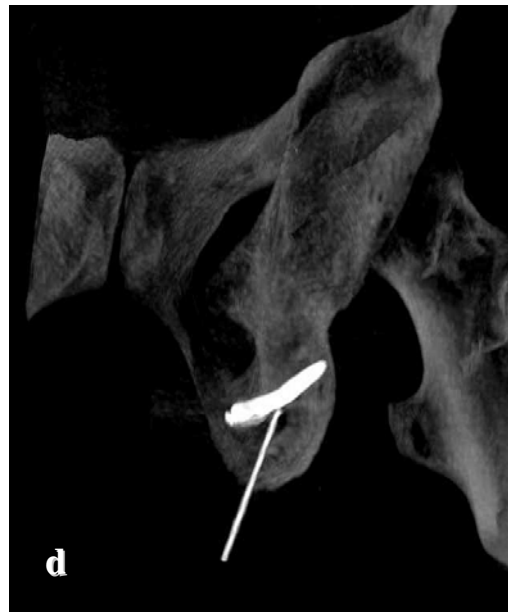a. Positioning the patient



c. Infiltration



b. Nerve stimulation



d. Location control of the injection

Fig 5 Infiltration under fluoroscopy with nerve stimulation control

1. Infiltration technology: Localizing the Alcock's canal can be difficult and is performed under fluoroscopy, ultrasound or CT-guidance or simultaneous electrical stimulation as in plexus anesthesia.
2. The time interval between the nerve compression and diagnosis: the shorter the interval and the younger the patient is, the more successful is the infiltration.
3. Compression of several sites along the anatomical nerve path.
4. Associated proximal lesions, like spinal stenosis, disc pathology, or a previous stretching of the nerve, which reduces its strength and ability for regeneration.
5. Neurovegetative component: 30% of the fibers of the pudendal nerve belong to the sympathetic nervous system.
6. Psychogenic component, due to the chronic pain.
7. Frequent occurrence of associated urogenital, anorectal, muscular and osteo-articular disorders.

In each case, infiltration of the Alcock canal is the key to the diagnosis. The temporary improvement or the disappearance of the symptoms after the infiltration helps to select those patients who will improve with a surgical decompression of the nerve.

b) Surgical Decompression

Two approaches are possible:

1. The endovaginal or perineal approach: This access can allow decompression of the Alcock's canal and, with more difficulty, the narrowed sacrotuberal area also. This approach was described by Shafik [13]. While it is easily feasible in females, it is relatively difficult in males.
2. The transgluteal approach: This was described in detail by R. Robert [14]. It

gives an excellent exposure to the sacrotuberal narrowing, and if necessary allows access to resect ischial spines. This permits re-alignment of the nerve in the pelvis, and thus the recovery of disturbances within the range of the obturator fascia, the processus falciformis, and the sacro tuberal ligament, which can cause pressure on the nerve when sitting. Surgical posterior transgluteal decompression performed on 106 patients was effective in 69 (66.1%) of the cases one year after surgery. 37 patients had no improvement of pain. No degradation of symptoms was noted. The alleviation of pain using this technique is rarely immediate. Frequently one observes a precipitous increase of the pain after freeing of the nerve. We infiltrate the nerve during the operation with long-acting local anesthetics. The 106 patients were examined post-operatively after 3, 6 and 12 months. (Table 2 – Fig 6) Our results reflect those in the literature: After 12 months an improvement or a healing could be observed in 69 cases (66,1%), and the patients took no further analgesics. In 37 cases (33,9%) no

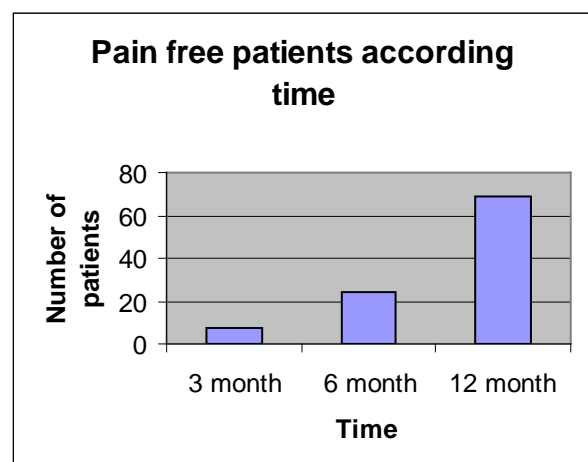


Table 2 - Fig. 6 Number of pain free patients according time after trans gluteal pudendal nerve decompression



improvement was reported. There was however, no degradation of the symptoms [11,12,14,15].

c) Future

A recent study has been published describing a laparoscopic pudendal nerve neurolysis.

Twenty male cadavers were operated using this technique. A good neurolysis depends on an optimal opening of the area of operation. Under this condition a decompression of the pudendal nerve could be accomplished in 16 (80%) of the cadavers. [16].

Summary

The pudendal nerve, a low-lying pelvic nerve, can be compressed in several sites. Such compressions can lead to pain syndromes, which are difficult to diagnose. One must think of pudendal nerve compression when confronted by unilateral, burning perineal pain in the area supplied by the pudendal nerve, which is exacerbated by sitting. The diagnosis

is based on the infiltration. This can also be therapeutic in 20-40% of the cases. In 60-70% of cases, surgical decompression leads to the healing. The pain relief however, is not immediate and the patients must be informed about this fact in advance. A multidisciplinary approach to care and support is essential.

Literature

1. Laubichler W (1978) Traumatische Läsionen des Nervus pudendus. *Akt Neurol* 5:47-50
2. Robert J, Labat JJ, Lehur PA, Glemain P, Armstrong O, Leborgne J, Barbin JY (1989) Réflexions cliniques neurophysiologiques et thérapeutiques sur le nerf pudendal (honteux interne) lors de certaines algies périnéales. *Chirurgie* 115:515-520
3. Antolak SJ, Hough DM, Pawlina W, Spinner RJ (2002) Anatomical basis of chronic pelvic pain syndrome: The ischial spine and pudendal nerve entrapment. *Med hypotheses* 59(3):349-353
4. Robert R, Prat-Pradal D, Labat JJ, Bensignor M, Raoul S, Rebai R, Leborgne J (1998) Anatomic basis of chronic perineal pain: Role of the pudendal nerve. *Surg Radiol Anat* 20:93-98
5. Hough DM, Wittenberg KH, Pawlina W, Maus TP, King BF, Vrtiska TJ, Farrell MA, Antolak SJ Jr. (2003) Chronic perineal pain caused by pudendal nerve entrapment: Anatomy and CT-guided perineural injection technique. *AJR* 181:561-567
6. Labat JJ, Robert R, Bensignor M, Buzelin JM (1990) Les névralgies du nerf pudendal (honteux interne): Considérations anatomocliniques et perspectives thérapeutiques. *Journal d'urologie* 96(5): 239-244
7. Amarenco G, Lanoe Y, Ghnassia RT, Goudal H, Perrigot M (1988) Syndrome du canal d'Alcock et névralgie périnéale. *Rev Neurol Paris* 144,8-9 :523-526
8. Watanabe H, Chigira M (1993) Irregularity of the apophysis of the ischial tuberosity. *Int Orthop* 17(4):248-253
9. Thoumas D, Leroi AM, Mauillon J, Muller JM, Benozio M, Denis P, Freger P (1999) Pudendal neuralgia: CT-guided pudendal nerve block technique. *Abdom Imaging* 24(3):309-312



10. Kovacs P, Gruber H, Piegger J, Bodner G (2001) New, simple, ultrasound-guided infiltration of the pudendal nerve: ultrasonographic technique. *Dis Colon Rectum* 44(9):1381-1385
11. B. Roche, J.-C. Dembe, P. Mavrocordatos, J. Robert-Yap, A. Cahana (2004) Approche anatomo-chirurgicale des névralgies du nerf pudendal *Le courrier de l'algologie* 4 :109-112
12. B. Roche, J.-C. Dembe, W. Karenovics, J. Robert-Yap, A. Cahana (2005) Pudendusneuralgie Anatomisch-chirurgische Aspekte *Coloproctology* 2005;27 :236-41
13. Shafik A (2002) Pudendal canal syndrome: a cause of chronic pelvic pain. *Urology* 60(1):199
14. Robert R, Brunet C, Faure A, Lehur PA, Labat JJ, Bensignor M (1994) La chirurgie du nerf pudendal lors de certaines algies périnéales : évolution et résultats. *Chirurgie* 119:535-539
15. Mauillon J, Thoumas D, Leroi AM, Freger P, Michot F, Denis P (1999) Results of pudendal nerve neurolysis-transposition in twelve patients suffering from pudendal neuralgia. *Dis Colon Rectum* 42(2):186-192
16. Loukas M, Louis RG, Tubbs RS, Wartmann C, Colborn GL (2008) Intra-abdominal laparoscopic pudendal canal decompression: a feasibility study. *Surg Endosc* 22(6):1525-1532