

Complicated Anal Fistulas

Prof. Gennaro Rosa

When an anal fistula still has not healed after surgical intervention, the surgeon is inclined to classifying it as a complicated one. Morphology of the main passage and of secondary extensions are the objective parameters that must be taken into consideration when classifying the treatment of fistulas as complicated.

Alan Parks' classification of the main fistulous tracts is currently the most adopted.(1). This classification has been modified (2) in order to include intrasphincter fistulas since like other types have been treated through fistulotomy or fistulectomy (fig. 1).

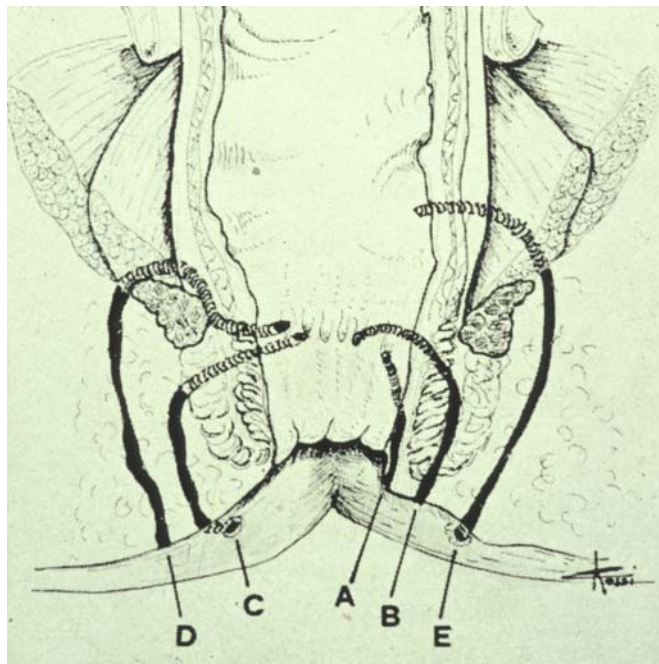


Fig.1- The revised classification of Parks.

Possible complications linked to the treatment of the main passage may arise. Muscular section is required in the majority of cases of fistulas, but in fistulotomy, fistulectomy or in a combination of both these two traditional methods in which it is adopted, it is not the cause of the complication of a fistula.

The need to extend the sphincter section is on the other hand, an objective parameter, sign that treatment is complicated. This may occur in patients with high transsphincter fistulas, those with fistulas above the sphincter and with extra sphincter fistulas, regardless of the sphincter's healthy function; partial sphincter section may also occur rarely in patients with middle or low trans-sphincter and intersphincter fistulas, in elderly and in patients that have already undergone sphincteric section for different

reasons, and in those who have more than one fistula.(3)

Anterior transsphincter fistulas carry a risk of incontinence even in the case of secondary sections, this is owing to the absence of the puborectalis muscle anteriorly, and this risk is greater in female patients because usually the anal canal is shorter. From what has been explained previously, it is necessary to check in all cases functionality by means of anorectal manometry, before deciding to section.(4)

As to the second parameter taken into account when evaluating the complication of treatment of anal fistulas, that is to say, secondary extensions, it is necessary to acknowledge that they all present some complications.(5)

It is therefore necessary to recognise their morphology before an actual operation. Secondary extensions may be directed upwards, or shifted to the front or the back as regards the sphincteral cylinder, or they may follow a semi-circular course in the inter-sphincter space (rarely), in the ischioanal spaces (more frequently), or in the rectal pelvis spaces. The frequency of secondary extensions in relation to the typology of the main passage is virtually

zero in intrasphincter fistulas, of 43% in trans-sphincter ones, of 68% in fistulas situated above the sphincter, of 100% in extra sphincter fistulas.(3)

Secondary extensions are a frequent cause of failure in healing or of a relapse; therefore they are worth a more detailed description.(6)

Secondary extensions directed upwards may make their way through the inter-sphincteric space (fig. 2)

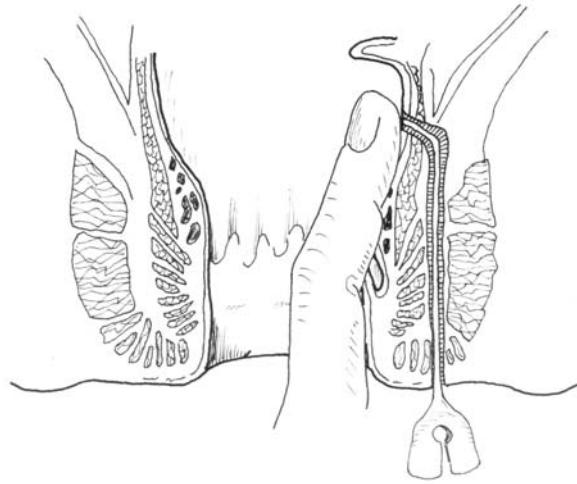


Fig. 2 High intramural extension of inter sphincter fistula.

Proximally between the circular and the longitudinal layer of the ampulla's wall, or in the ischioanal space (also called ischioanal) (fig.3)

or above the elevator of the anus in the recto-pelvis space. (Fig.4)

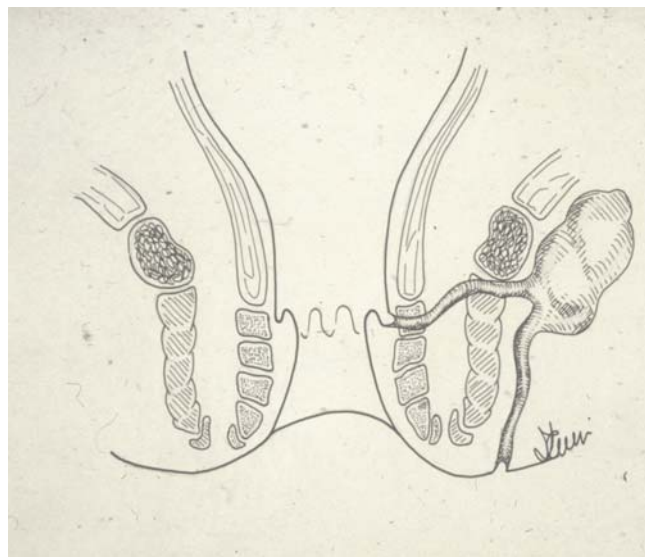

Fig. 3 High ischioanal extension of transsphincter fistula.

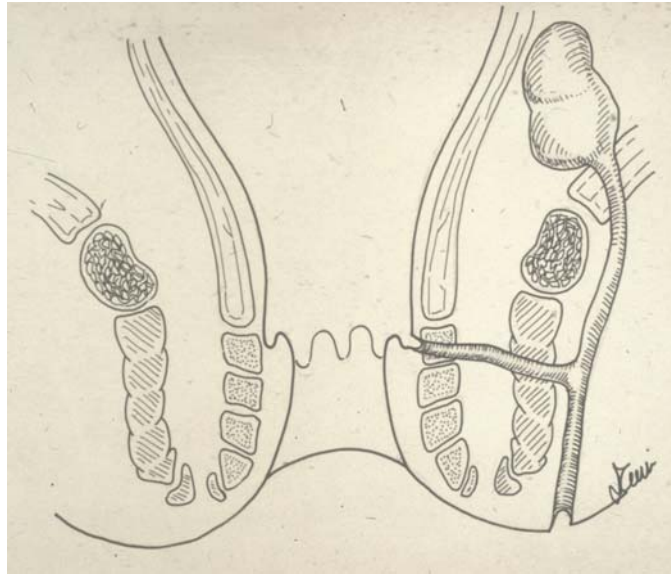


Fig 4 High recto-pelvis space extension of transphincteric fistula.

Anterior secondary extensions are directed towards the scrotum in men and towards the vulva and the vagina (anovulvar and anovaginal

extensions) in women. Posterior extensions affect the deep post-anal space (fig.5)

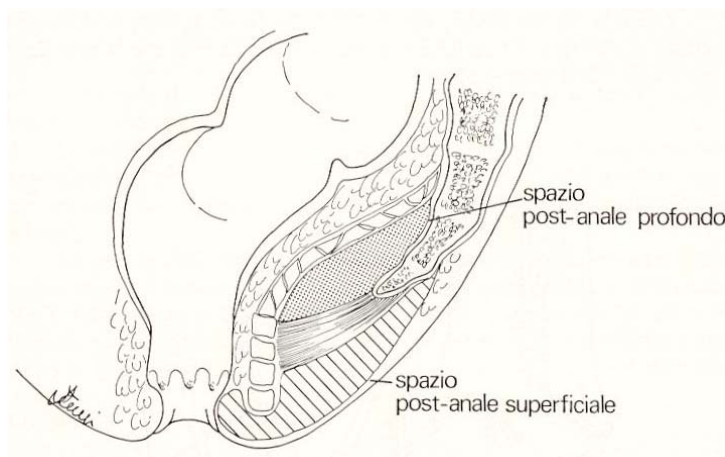


Fig 5 Secondary extension in the deep post-anal space.

Secondary circumferential extensions may be

intersphincteral, ischiorectal bilateral or
pelvirectal bilateral. (fig.6)

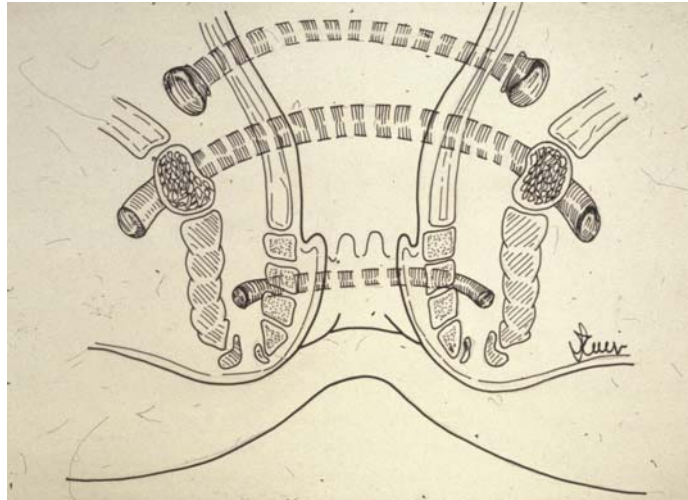


Fig. 6 Secondary circumferential extensions.

There are rare abnormal or odd secondary extensions that affect the muscles of the gluteus or the posterior muscles (cavities) of the thigh.

It is not difficult to diagnose an active anal fistula; mention, in the anamnesis, of a purulent discharge from an external anal orifice, or in fistulas, of purulent discharges which have their course and outflow inside the anus, lead to a correct diagnosis. The diagnosis of the abscess may be difficult, when there is no tumor outside

the anus and intense pain does not allow carrying out an anorectal exploration.

It is not always easy to gather the presence of a complicated fistula, however, there are some indications, other than more sophisticated instrumental examinations, which make one suspect a complicated fistula.

Amongst the most important, the great distance from the cutaneous orifice of the anus (fig.7).

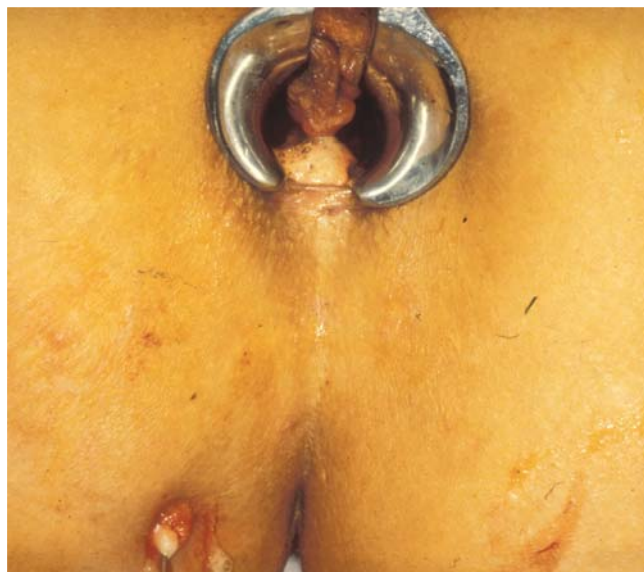

Fig. 7 Cutaneous orifice of over-sphincteric fistula.

The fistula is complicated in case of presence of two or more secondary orifices, as in fistulas with bilateral ischioirectal extension (a horse shoe fistula), the recognition of a hardening in correspondence with the anorectal ring, or the ischioirectal spaces, during digital exploration, or in case of perception of a fluctuation or of a hardening during palpation of the pelvirectal space. Also the examination by means of a specillum, of an ever-itching cutaneous orifice, leads one to suspect a complicated fistula, if the instrument enters easily in depth (this manoeuvre is not recommendable in the case of inexperience or intense pain).

The lack in finding the primary endoanal orifice makes it difficult to treat an anal fistula due to the uncertainty of the type present.

Anoscopy must always be carried out; and may reveal the primary orifice, or lead to the suspect of one in a deep anal crypta, where a scar is palpated through digital exploration.

Rectoscopy too, by means of a rigid tube, must always be carried out in the case of an anal fistula: It may give information about the wall of the rectum, possible tumefaction at this level; it may reveal secondary rectal orifices, and inform about possible associated diseases.

Amongst the most important examinations, fistulography can not be considered a reliable means. Once widely practised, because of the frequent lack of visualization of the entire course of the main passage and of its possible expansion.

Very reliable, on the other hand, and frequently used is the endoanal ultrasonography with rotating sound, combined to the introduction of H₂O₂ into the fistulous tract in order to obtain a greater contrast; three-dimensional computerized reconstruction offers very impressive pictures, however in very complicated cases, in cases have been operated more than once, in relapses of

abscesses, it isn't easy, and at times it is impossible to distinguish the post-operative fibrosis from a purulent concamerated gathering; in these cases a CAT or a MR may add useful elements to the diagnosis.

The treatment of a complicated anal fistula is not different to a so-called simple fistula, at least in its outlines.

The widening of the margins of the main passage, the opening and the drainage or the excision, when possible, of the secondary extensions, is the cornerstone of every traditional surgical treatment in opposition to the more recent but less documented treatment with regard to its results in long term followup, such as the advancement flap and fibrin glue. Fistulotomy of the main passage is carried out immediately if the size of the muscular section is limited and no impact on continence is feared. In all other cases it is extended with Seton or with elastic. Seton must be kept loose in the main passage and only after the test of a good perisphincteral fibrosis (usually after a period variable between 2 to 6-8 months.) the surgical section of the sphincter can be done. I am not in favour of the "cutting seton" that is of a Seton which is progressively narrowed in its circumference with progressive muscle section; in these cases elastic is the best choice because it allows a more accurate graduation of the section. If, after the application of a seton, the muscular surgical section entails an excessive divaricating of the muscles, the procedure is interrupted and a seton is put around the sphincter once more.

Treatment of secondary extensions depends on their morphology.

Total opening and widening of the margins is the ideal treatment but not always feasible; anterior extensions that are directed towards the scrotum may be largely opened and enclosed without fear; the vast wound heals within some weeks.(fig.8)

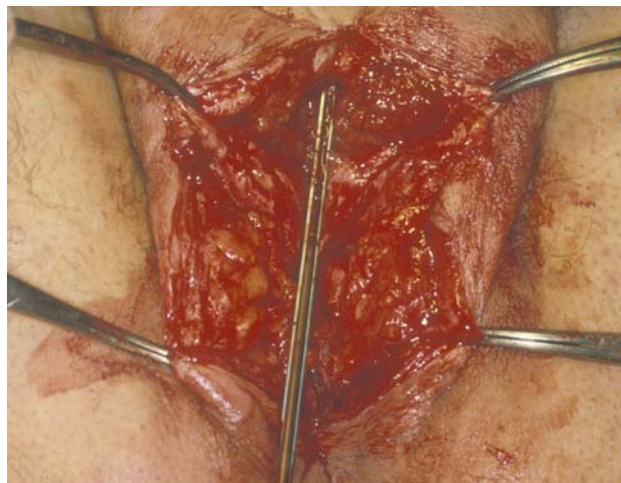


Fig. 8 Extensive opening of a secondary extension of the scrotum.

The extensions to one or both ischio-rectal spaces can be vastly opened and enclosed too (7), in

order to obtain a wound that can be easily examined.(fig 9)

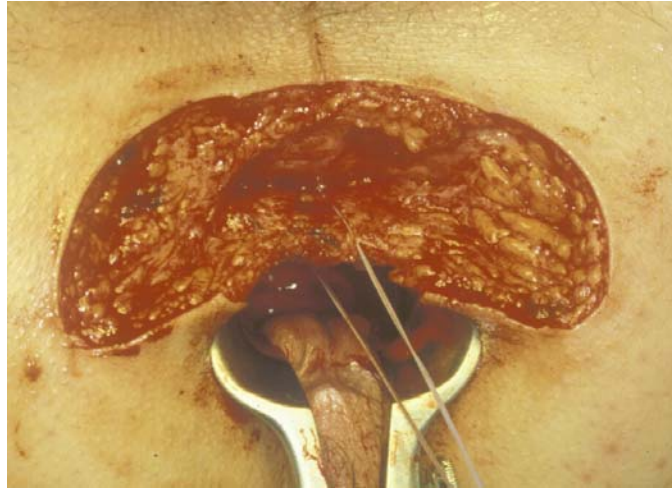


Fig. 9 Extended fistulectomy of secondary bilateral ischio-rectal extension.

The remarkable loss of cutaneous and adipose tissue must not cause fear; no sign of deformity

will remain after the healing process.(fig.10)

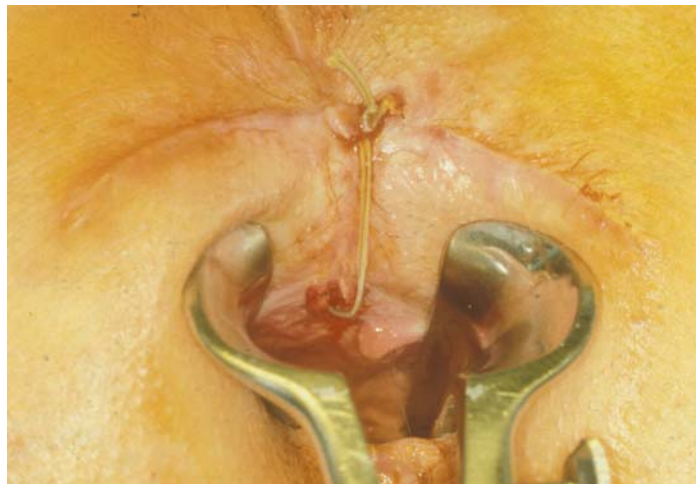

Fig. 10 Same cases: extended fistulectomy of secondary bilateral ischio-rectal extension.

Sometimes it is necessary to settle only for the total opening of a secondary extension without proceeding to the widening of the margins, as in the case of a high intramural extension of an inter-

sphincteric fistula, which has to be opened and drained via the endoanal and not the ischio-rectal space, which would lead to the iatrogenic formation of a supra-sphincteric fistula (fig 11).

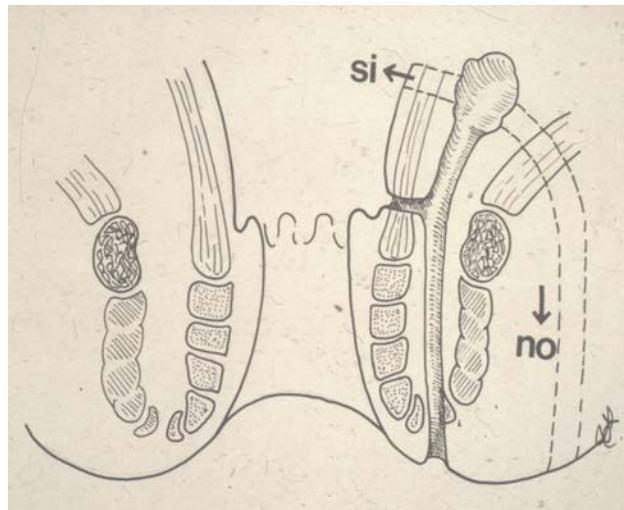


Fig. 11 Endoanal opening of a secondary intramural extension.

The secondary extension in the deep post-anal space may be opened adequately only by means

of a disinsertion of the heavy anorectal mass of the coccyx. (fig 12)

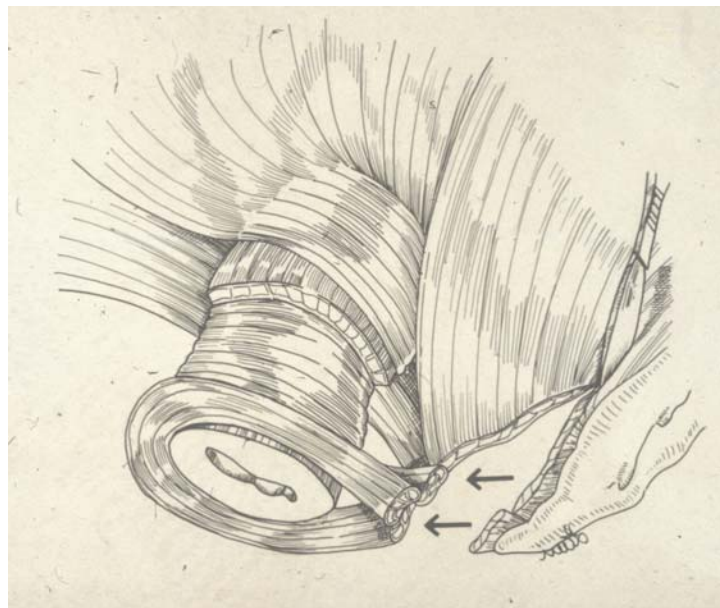


Fig. 12 Opening of the deep post-anal space.

Some secondary extensions should be limited to a partial opening, as for example the monolateral

pelvirectal extensions, where the levator ani may be sectioned only partially to improve drainage.

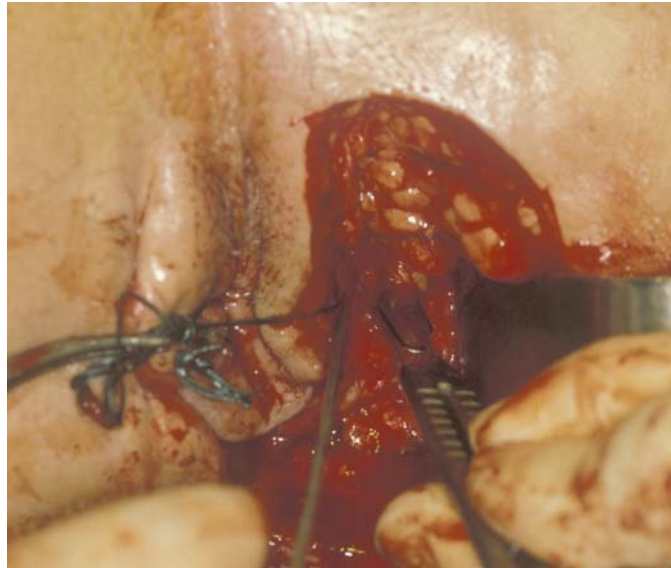

Fig. 13 Section of the elevator of the anus in pelvirectal extension.

Extended opening and widening of the margins of a secondary extension and the simple fistulotomy of the main passage (immediate or with seton) fulfils a method very useful in treating complicated fistulas based on mixed approaches, that is a combination of fistulectomy and fistulotomy.

Great attention is paid to the postoperative period, which means following the repair processes, ready to discover any fistula or abscess had not been noticed previously. Bearing in mind this objective, it should be considered mandatory that the patient should be assisted throughout his postoperative course by the surgeon who operated him. Wide wounds facilitate inspection

and digital exploration without pain, on the contrary to narrow and deep ones.

In case of doubt one must not hesitate to take the patient into the operating theatre for a revision in sedation or in anaesthesia.

This applies to fistulas with a pelvirectal extension and for the intramural extensions in which drainage is always precarious, and must be frequently checked and improved.

These simple rules may be of help in the treatment of complicated fistulas, in order to reduce the rate of failed healings and relapses and therefore of a second operation, with possibly new and often not resolute sphincter sections that increase the risk of incontinence.

References

1. Parks A G, Gordon P H, Hardcastle J D: A classification of fistula-in-ano. Br.J.Surg. 63: 1-12, 1976.
2. Rosa G, Rossi C, Gagni G, Sannini I: Fistole anali. Attuali orientamenti di terapia chirurgica. Piccin Ed. Padova pagg. 55-56, 1979.
3. Parks A G, Stitz R W: The treatment of high fistula-in-ano. Dis.Colon Rectum 19:487-491, 1976.
4. Rosa G, Baggio E, Cevese M: Il ruolo della elettromanometria nella patologia anorettale. Ann. Gastroenterol. Hèpatol. 16/5: 373-377, 1982.
5. Rosa G, Baggio E, Gandolfi P, et Al: Fistole anali difficili. Riv. It. Colproct. 2: 283-286, 1983.
6. Rosa G, Baggio E, Sannini I, et al: Il trattamento delle fistole anali cosiddette "alte e difficili". Riv. It. Colproct. 1: 139-151, 1982.
7. Rosa G, Baggio E, Marafetti C, et al: La chirurgia degli ascessi e delle fistole ischiorettali a ferro di cavallo. Riv. It. Colproct. 3: 263-272, 1984.