



## Hybrid Robotic Proctectomy for Rectal Cancer: Results and Potential Benefits

---

*Meng Wang<sup>#</sup>, Jonathan E. Efron<sup>\*</sup>*

**\* Corresponding Author:**

**Jonathan E. Efron**

**Johns Hopkins Hospital**

**Department of Surgery, Ravitch Division, MD, 21287, USA**

**# Department of General Surgery, The Affiliated Drum Tower Hospital, School of Medicine, Nanjing University, Nanjing, Jiangsu Province, 210093, China**

---

### Abstract

#### Introduction

Although robotic techniques have induced a tremendous revolution in the field of minimally invasive surgery, its application in rectal cancer is still not widely accepted. Hybrid procedure was the most common technique used in robotic proctectomy. The aim of this review was to assess the potential benefits of hybrid robotic technique in rectal cancer surgery.

#### Methods

A system review of the literature using the PubMed search engine was undertaken to identify relevant articles. The clinical outcomes were evaluated by operative times, conversion rates, first time to flatus, hospital days, and complications. The oncologic outcomes were evaluated by TNM stages, number of lymph nodes retrieved, positive margins and survivals.

#### Results

Thirteen studies were assessed for overall outcomes and comparison with laparoscopic/open surgery. Totally 859 patients (535 men and 324 women), were

included in this review. The median operative time was 296 minutes (190.1-352.7), and the conversion rate was 2.6%. The anastomotic leakage (8.1%) was the most common complication, followed by ileus/obstruction (6.4%), abscess (3.0%), wound infection (2.6%) and urinary retention (1.3%). After a median 17.4 months follow-up, the overall survival ranged from 86.5% to 97.4%. In addition, we found a lower conversion of robotic surgery compared with laparoscopic surgery in 7 comparative studies, and shorter hospital days in 2 comparative studies.

#### Conclusion

Hybrid robotic proctectomy is a feasible and safe surgery. Potential benefits of the robotic surgery include decreased conversion rates, better recovery, short learning curve, and less surgeon's fatigue. However, current data support the robotic benefits are still limited.

#### Keywords

Robotic surgery, rectal cancer, hybrid technique, proctectomy

## Introduction

During the past decades, laparoscopic surgery has been widely accepted for colorectal cancers. It has been reported to achieve better short-term outcomes than open surgery for rectal cancer [1]. Despite of the major benefits, there are still major challenges limiting laparoscopic surgeons' ability to perform proctectomies. These include the angle of the sacrum, narrow pelvis, bulky mesorectum or large tumour, low rectal division in obese patients or those with a narrow pelvis, and high conversion rates. Robotic surgery was developed in the early 1990s and rapidly applied in several specialities most notably urology for prostatectomies [2, 3, 4]. It presented better visualization, flexible instruments, and free movement in a confined space, which were assumed to overcome the challenges in laparoscopic proctectomy.

Robotic surgery for rectal cancer was firstly reported by Eric Vibert et al in 2001 [5]. Giulianotti et al then reported six rectal anterior resections and two abdominoperineal resections (APR) with robotic assistance in 2003 [6]. In 2006 Pigazzi et al reported on the concept of robotic total mesorectal excision

(TME) [7]. With the development of the robotic technique, many studies demonstrated the feasibility and safety of the robotic proctectomy [8]. In 2012, an international, multicenter, prospective, randomized, controlled trial (ROLARR) was designed to compare robotic-assisted versus standard laparoscopic surgery [9]. However, there was still no definite evidence of the robotic advantages in rectal cancer.

The robotic proctectomy may be performed via two methods: a totally robotic procedure or hybrid laparoscopic procedure [10]. The totally robotic procedure is performed by a complete robotic vascular ligation and robotic pelvic dissection, with or without splenic flexure mobilization [11]. The hybrid procedure is initiated utilizing laparoscopic instruments to perform colonic mobilization and vascular division followed by utilizing the robot for the pelvic dissection [12]. In this review, we describe the hybrid procedure for rectal cancer resection, assess the hybrid studies for rectal cancer from 2007-2013, and analyze the evidence supporting the potential benefits of robotic surgery.

## Materials and methods

The electronic database of Medline was reviewed using the PubMed search engine from 2007 Jan 1<sup>st</sup> to 2013 May 30<sup>th</sup>. The key words used for search include: robotic, robot assisted, Da Vinci, rectal cancer, proctectomy, total mesorectal excision (TME), low anterior resection (LAR), abdominoperineal resection (APR), intersphincter resection (ISR). Full texts from all articles were obtained. Inclusion criteria of system review was as follows: all the studies reporting outcome, follow up and complications of hybrid robotic proctectomy for rectal cancers. Exclusion criteria included: all studies on colonic cancer and benign disease were excluded; the early studies before 2007; studies in which total patients numbered less than 10; and studies with duplicate records were excluded. After an initial screen of 59 titles, 13 studies met the predefined inclusion criteria and 46 studies were excluded (shown in Figure 1).

The 13 studies were assessed for a system review of hybrid robotic proctectomy for rectal cancer [13-25]. The clinical outcomes were evaluated by operative times, conversion rates, first time to flatus, hospital days, and

complications. The oncologic outcomes were evaluated by TNM stages, number of lymph nodes retrieved, positive margins, and survivals.

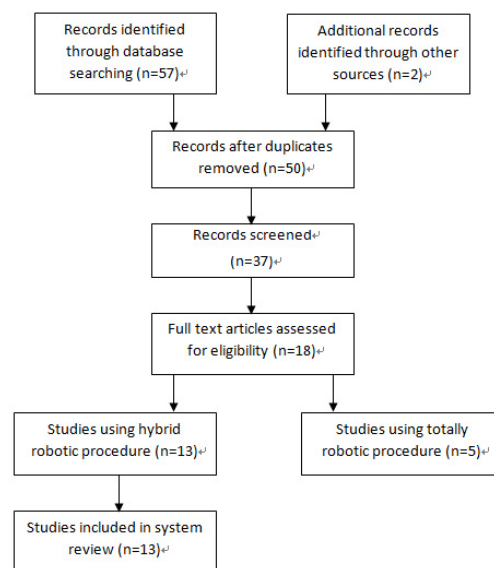


Figure 1 Flow diagram of studies selection for systemic review.

## Surgical Technique

Hybrid MIS robotic procedures require a similar set up to other MIS colorectal procedures. The patients are secured to the table in the lithotomy position with both arms tucked at their side and secured to the table with foam and tape or with the use of a beanbag. The ports are placed as shown in figure 2.

The left colon and splenic flexure is mobilized laparoscopically with division of the IMA, IMV. The mesentery of the colon is divided at the level of possible bowel division. The robot is brought directly between the legs and docked to the patient. At this point the patient has to be in steep trendelenburg with a neutral stance with respect to left right tilt. The rectal TME dissection is then performed with the robot. Division of the rectum is completed with a stapler or resection is performed through a mucosectomy with a hand sewn coloanal anastomosis if the rectal cancer is low. A loop ileostomy, if needed, is laparoscopically created.

### Port Placement

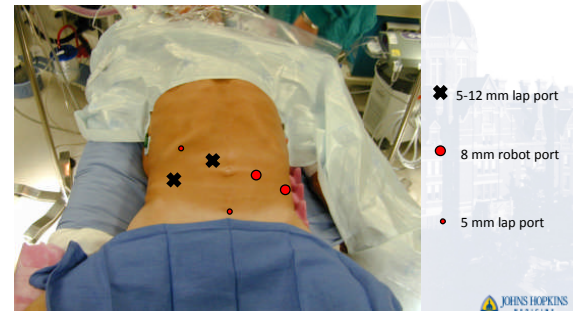


Figure 2. Port placement for hybrid laparoscopic robotic proctectomy.

## Results

Overall outcomes (Table 1)

Author	Hellan et al (13)	Balk et al (14)	Balk et al (15)	Patriti et al (16)	Park et al (17)	Piazza et al (18)	deSouza et al (19)	Kwak et al (20)	Baek et al (21)	Zawadzki et al (22)	Kang et al (23)	Baek et al (24)	Stanciulea et al (25)	System Review
Year	2007	2008	2009	2009	2010	2010	2010	2011	2011	2013	2013	2013	2013	2007-2013
<b>Characteristics</b>														
Total patients (n)	39	18	56	29	41	143	44	59	41	77	165	47	100	859
Mean Age (yr)	58*	57.3	60.3	68	61.2	62	63	60*	63.6	60.1*	61.2	58	62	61.2*
Gender (male %)	53.8	77.8	66.1	38.5	58.5	60.8	63.6	71.2	61	58.3	63	66	66	62.3
Mean BMI (Kg/m <sup>2</sup> )	26*	22.8	23.4	24	23.4	26.5	28.2*	23.3*	25.7*	28*	23.1	23.4	26	24*
Types of operation														
LAR/AR (%)	56.4	100	100	65.6	70.7	55.8	68.2	91.5	80.5	88	99.4	87.2	69	79.5
ISR/CA (%)	28.2	0	0	17.2	29.3	22.4	13.6	8.5	4.9	12	0	12.8	8	16.4
APR (%)	15.4	0	0	17.2	0	21.7	18.2	0	14.6	0	0	0	23	4.0
<b>Clinical outcomes</b>														
Mean operation time (min)	285*	217.1	190.1	202	231.9	297	347	270*	296	327*	309.7	352.7	NR	296*
Conversion (%)	2.6	0	0	0	0	4.9	4.5	0	7.3	3.9	0.6	2.1	4	2.6
First time off table (days)	2	1.8	1.9	NR	2.9	2.7	NR	NR	2.3	NR	2.2	NR	4	2.2*
Hospital days (days)	4	6.9	5.7	11.9	9.9	8.3	5	NR	6.5	6.4	10.8	9	10*	6.9*
Overall complications (%)	12.8	22.2	10.7	30.6	29.3	41.3	13.6	32.3	22	24.6	20.6	19.1	18	22*
Anastomotic leakage (%)	12.1	0	1.8	6.8	9.7	10.5	5.6	13.6	7.3	6.4	7.3	8.5	9	8.1
Ileus/obstruction (%)	12.8	0	1.8	6.8	2.4	12.6	4	8.5	7.3	7.8	3.6	4.2	4	6.4
Abscess (%)	0	0	0	0	4.8	7	0	0	4.8	2.6	4.2	4.2	1	3.0
Wound infection (%)	5.1	0	0	3.4	0	2.8	2	1.7	0	10.4	0.6	2.1	4	2.6
<b>Oncologic outcomes</b>														
TNM														
Stage I (%)	20.5	0	0	0	0	12.6	9.1	5.1	17.1	NR	0	12.8	5	6.6*
Stage II (%)	33.3	27.8	39.3	37.9	31.7	25.2	31.8	27.1	29.3	NR	33.9	46.8	24	31.3*
Stage III (%)	10.3	22.2	28.6	31	34.1	25.2	34.1	39	9.8	NR	30.9	17	43	29.3*
Stage IV (%)	33.3	50	32.1	24.1	34.1	37	18.2	20.3	36.6	NR	32.7	21.3	21	29.9*
Lymph nodes retrieved (n)	2.6	0	0	6.9	0	6.8	8.5	7.3	NR	0	0	2.1	7	2.8*
Positive margin rate (%)	13*	20	18.4	10.3	17.3	14.1	14	20*	13.1	12.9	15	10.6	14	14*
Follow up time (months)	0	0	7.1	0	4.9	0.7	2.3	1.7	2.4	3.9	4.2	2.1	NR	2.3*
Overall survival (%)	13	NR	14.3	29.2	NR	17.4	NR	17*	NR	NR	22.4	31.5	24*	17.4*
Disease free survival (%)	97.4	NR	96	96.6	NR	97	NR	NR	NR	NR	NR	86.5	93	86.5-97.4
	89.7	NR	NR	NR	NR	77.6	NR	NR	NR	NR	83.5	80.6	NR	77.6-89.7

\* = median value \* = among 782 patients NR= not reported BMI=body mass index, LAR= low anterior resection, AR= anterior resection, CA= coloanal anastomosis, ISR= intersphincter resection, APR= abdominoperineal resection.

Table 1: System review of data in the hybrid robotic studies for rectal cancer (2007-2013)

A total of 859 patients (535 men and 324 women), were included in this review with a median age of 61.2 year (range 57.3-68 years) and a median BMI of 24 kg/m<sup>2</sup> (range 22.8-28.2 ). All the operations were performed via the hybrid laparoscopic robotic approach (shown in Table 1). The median operative time was 296 minutes (190.1-352.7). Among the 859 patients, 683 underwent anterior resection/ low anterior resection (79.5%), 141 underwent intersphincteric resections with coloanal anastomosis (16.4%), and 34 had abdominoperineal resections (4.0%).

Our review identified total 22 conversions (a conversion rate of 2.6%). There was no 30-day operative mortality. Anastomotic leakage was the most common complication with a rate of 8.1%, followed by ileus/obstruction (6.4%), abscess (3.0%), wound infection (2.6%) and urinary retention (1.3%). The median complication rate was 22% (range 10.7%-41.3%). We observed a median first time of flatus in 2.2 days and a median length of hospital stay for 6.9 days.

782 patients in this review had oncologic outcomes described. There were 52 patients with stage 0 disease(6.6%), 245 stage I patients (31.3 %), 229 stage II patients (29.3 %), 234 stage III patients (29.9 %), and 22 stage IV patients ( 2.8 %). The median numbers of retrieved lymph nodes was 14 (range 10.3-20) and the median positive margin rate was 2.3% (range 0-7.1%). After a median 17.4 months follow-up, the overall survival ranged from 86.5% to 97.4% and disease free survival ranged from 77.6% to 89.7%.

### Robotic versus laparoscopic proctectomy

Comparison between robotic and laparoscopic proctectomy were assessed in 7 studies (2 case matched studies, and 5 unmatched) [14,15,16,17,20,21,23,24]. A total of 349 hybrid robotic cases and 374 laparoscopic cases were included. In 3 studies, the conversion rates in robotic groups were significantly lower than in laparoscopic groups [15, 16, 23]. Baik et al reported a conversion of 0.0% in robotic group and 10.5% in laparoscopic group (p=0.013) [15]. Patrìti et al reported a lower robotic conversion (p<0.05) and Baik et al found the lower conversion of robotic surgery compared with laparoscopic surgery (2.1% vs 16.2%, p=0.02) [16, 23]. In the other 5 studies, the conversions of robotic cases were lower than those of laparoscopic cases, although the differences did not reach statistical significance [14, 17, 20, 21, 24]. A recent meta-analysis supported a significantly lower

conversion rate in robotic surgeries (p=0.03, 95% CI 1-12) [26]. Another meta-analysis of non-randomized robotic studies also showed reduced conversion to open surgery (RR=0.31, 95% CI 0.12, 0.78) [27]. The lower conversion rate for robotic surgery is encouraging, especially considering the high proportion of distal rectal cancer.

Another potential benefit of robotic proctectomy is shorter hospital stay. In our review, 2 studies mentioned the hospital days were shorter in the robotic group than in the laparoscopic group (9 vs 11 days, p=0.011; 6.9 vs 8.7, p<0.001) [14, 24]. Kwak et al reported a longer operating time in the robotic group (P <0.0001), and Park et al reported 168.0 ± 49.3 min for laparoscopic group and 231.9 ± 61.4 min for robotic group (p<0.001). There were no significant differences in mortality, complications, lymph nodes retrieved, positive margins, and overall survival or disease free survival between robotic and laparoscopic surgeries. Finally, the higher cost of robotic surgery was mentioned in Baik's study [21].

### Robotic versus open proctectomy

In this review, Kang's study was the only analysis between open surgery and hybrid robotic surgery [23]. The time to first flatus and hospital days in the robotic surgery (RS) group were significantly shortened compared with the open surgery (OS) group (p<0.001). The circumferential resection margins involvement was significantly lower in the RS group than in the OS group (4.2% vs 10.3%, p=0.034). No significant difference in disease free survival was observed between two groups. Another study that describe a complete robotic technique demonstrated the bowel peristalsis returned one day earlier in the RS group than in the OS group (p<0.001) [28], though the significance of this is unknown.

### Hybrid versus totally robotic procedure

Author	Choi et al [20]	Bianchi et al [21]	Leong et al [24]	Kim et al [23]
Year	2009	2010	2011	2012
Total patients (n)	50	25	29	100
Age (yr)	58.5	69	61.5 *	57
Gender (male %)	64	72	79.3	71
BMI (Kg/m <sup>2</sup> )	23.2	24.6	23.3 *	24.0
operative time(min)	304.8	240	325 *	NR
Conversion (%)	0	0	0	0
Lymph nodes retrieved (n)	20.6	18	16 *	20
Positive margin rate (%)	2	0	3	1.0
Overall complications (%)	18	16	31.0	NR
Anastomotic leakage (%)	8.3	4	10.3	2
Woundinfection (%)	0	4	0	NR
Abscess (%)	0	0	0	NR
Ileus/obstruction (%)	6	0	13.8	3
First time of flatus (days)	2.6	2	2	2.1
Hospital days (days)	9.2	6.5	9	7.1
Follow up time (months)	NR	10	NR	NR
overall survival (%)	NR	100	NR	NR
Disease free survival (%)	NR	NR	NR	NR

NR=not reported a=median value

Table 2: Review of some studies using totally robotic procedures

Currently, studies that compare the difference between hybrid and totally robotic procedures are rare. In a combined study, including 269 totally robotic cases and 120 hybrid cases, there was no significant difference in the complication rate between two procedures [29]. We reviewed some recent studies using totally robotic procedure for rectal cancer (Table 2) [30, 31, 32, 33]. The operative time ranged from

240 to 325 minutes and complications ranged from 16% to 31%. There were no conversion cases in these studies. According to a short-term study in 2012, the totally robotic surgery has equal oncologic safety, functional outcome, and morbidities to open proctectomy [33].

---

## Discussion

Since the development of the Da Vinci robotic system, the robotic technique has been rapidly adopted and led an evolution in minimally invasive surgery. In 2007, approximately 50,000 robotic prostatectomies were performed, accounting for 60% of radical prostatectomies performed in USA [34]. Urologists seem to prefer the robotic approach in radical prostatectomy because the technique demonstrates particular benefits in a confined space.

These benefits can be utilized for rectal cancer surgery. They include: equal access to both sides of the pelvis; multi articulated instruments with monopolar or bipolar coagulation and now vessel sealing capability; generating large forces of torque, which is beneficial in obese patients, or those with bulky rectal lesions; a better view in a narrow pelvis, and more freedom of movement. The improved optics while sitting at the robotic platform may also benefit in identifying nervous and vascular structures.

While robotic prostatectomy has become the most widely accepted method of prostatectomy, robotic proctectomy remain far less widely accepted. From 2009-2010, robotic assistance was used in only 2.78% of 128,288 colorectal operations in USA [35]. What factors blocked the adoption of the robotic technique in rectal cancer? Compared with prostatectomy a one quadrant operation, proctectomy is a multiple quadrant operation requiring work in 3 separate abdominal quadrants (the left upper, left lower quadrant, and the pelvis) to enable splenic flexure mobilization and intra or extra-corporeal anastomosis. The robotic technique, however only provides benefits over straight laparoscopy in pelvis. The hybrid approach appears to provide the best of both worlds for the minimally invasive colorectal surgeon. There are other detriments of the hybrid or robotic procedure that have limited its use. These include increased operative time, loss of haptic feedback, additional cost of patients, and learning curve for surgeons, limited the

attraction of robotic technique for rectal cancer.

### Potential benefits

Despite the perceived difficulties with robotics and the precise nature of total mesorectal dissection, rectal cancer is still the number one indication for the use of the robot in colorectal surgery (39.52%) [35]. Debate exists to the technical ease of laparoscopic TME, but studies document high conversion rates to open procedures implying the difficulty of the procedure. Oktar et al reported a conversion rate of 6.4% in 513 laparoscopic surgeries performed for rectal cancer [36]. They found the converted patients had a higher risk of complications and recurrence. A hybrid technique was advocated to overcome these limitations. Following laparoscopic colonic mobilization and vascular ligation, surgeons turned to robotic platform and performed the gold-standard TME with flexible instruments and better visualization. In this review, the total conversion rate of 859 robotic cases was 2.6%, and 7 comparative studies demonstrated that hybrid robotic proctectomy was associated with lower conversions compared with strict laparoscopic surgery.

In addition, two studies observed shorter length of hospital stay [14, 24]. A system review in 2013 suggested that robotic rectal surgery could potentially offer better short-term outcomes especially in selected patients [37]. The prospective randomized trials looking at robotics and laparoscopy for rectal cancer have found these techniques to be equal or superior with respect to complications, mortality and oncologic outcomes. Further studies need to be observed to determine nerve preservation, postoperative life quality, and long time survivals.

Fatigue of surgeons, another potential benefit of robotic surgery, was always neglected in historical studies. Surgeon fatigue seems to be less with the robotic pelvic procedures than with standard laparoscopy or open procedures, but definitive data does not exist.





The robotic system generates the large mechanical forces needed for rectal mobilization as opposed to the surgeon manually generating these forces. This is particularly noted in obese patients. Ahlering et al studied the learning curve for robotic prostatectomy and reported that the robotic operative system might significantly shorten the learning curve for an experienced open yet naive laparoscopic surgeon<sup>[38]</sup>. The operative time and console time of robot surgery in rectal cancer operations starts to demonstrate a decrease after 20 cases<sup>[39]</sup>. A similar study suggested that the estimated learning curve for robotic assisted rectal cancer surgery was achieved after 21-23 cases<sup>[40]</sup>.

As to these studies, we conclude the robotic approach may have potential benefits such as decreased conversion rates, shorter learning curve, decreased surgeon's fatigue, especially in selected patients. However, current data support robotic potential benefits were still limited.

### Challenges and Tendency

Besides the limited support in potential benefits, some challenges must be overcome by surgeons before wide application of robotics may be accepted. Loss of haptic feedback generated large forces of torque, tearing intestinal wall, vessels and mesorectum, which may induce injuries during robotic surgery<sup>[41]</sup>. Increased SSI risk (9.68-70.00, 95% CI) was reported in robotic colorectal surgery compared to open surgery in one study<sup>[42]</sup>. Errors in low volume centers were also reported as being higher such as ureter division<sup>[43]</sup>. Increased training and a shortened learning curve helped to overcome

these challenges, and progress can be aided by visual feedback and adaptive regional feedback.

The cost of robot surgery is another matter of debate. The robotic system itself costs nearly \$1.7 million, with yearly maintenance cost of up to \$ 100,000<sup>[44]</sup>. The costs for patients vary in different medical institutions. Some costs are difficult to calculate, including the cost of training surgical staff and time consumed in the docking process. It is critical to consider the balance of costs and benefits. Some reports have assessed the cost efficiency of robotic surgery compared with other treatments<sup>[45, 46]</sup>. However, less expensive technologies should be found to overcome the cost efficiency challenge.

During the last 10 years, some new robotic techniques have been advanced for rectal proctectomy. Prasad et al described a novel robotic purse-string technique in low anterior resection, which expanded the indications in ultra-low rectal cancers<sup>[47]</sup>. Ja Park et al reported a "reverse" hybrid procedure, which involved reversal of the operative sequences with robotic vascular and rectal dissection before laparoscopic colonic mobilization<sup>[48]</sup>. In 2009, Choi et al reported an approach of robotic proctectomy with transanal or transvaginal retrieval of the specimen<sup>[49]</sup>. Fluorescence imaging, a new technology used to evaluate perfusion of the distal colon, was available for coloanal anastomosis in robotic surgery<sup>[50]</sup>. It has been proposed that it may decrease the anastomotic leakage rates in robotic proctectomy. These approaches modified the robotic technique and promoted the advantages found in robotic surgeries.

---

## Conclusion

In this review, we assessed the rectal cancer studies using hybrid robotic technique from 2007 to 2013. Our results demonstrated hybrid robotic proctectomy was a feasible and safe surgery with acceptable short term outcomes. Potential benefits of the robotic surgery include decreased conversion rates, better recovery, short learning curve, and lessening

of surgeon's fatigue. However, current data support the robotic benefits were still limited. Randomized clinical trials and longer follow-ups are needed to evaluate further benefits of robotic technique. There are still some obstacles to overcome before its wide application in rectal cancer..

---

## References

1. Arezzo A, Passera R, Scozzari G, et al. Laparoscopy for rectal cancer reduces short-term mortality and morbidity: results of a systematic review and meta-analysis. *Surg Endosc.* 2013; 27(5):1485-502.
2. Ewing DR, Pigazzi A, Wang Y et al. Robots in the operating room- the



- history. *Semin Laparosc Surg.* 2004; 11: 63-71.
3. Ballantyne GH. Robotic surgery, telerobotic surgery, telepresence, and telementoring. Review of early clinical results. *Surg Endosc.* 2002; 16: 1389-1402.
  4. Weber PA, Merola S, Wasielewski A et al. Telerobotic-assisted laparoscopic right and sigmoid colectomies for benign disease. *Dis Colon Rectum.* 2002; 45: 1689-1694.
  5. Vibert E, Denet C, Gayet B. Major digestive surgery using a remote-controlled robot: the next revolution. Vibert E, Denet C, Gayet B. *Arch Surg.* 2003; 138(9): 1002-6.
  6. Giulianotti PC, Coratti A, Angelini M, Sbrana F, Cecconi S, Balestracci T, Caravaglios G. Robotics in general surgery: personal experience in a large community hospital. *Arch Surg.* 2003; 138(7): 777-84.
  7. Pigazzi A, Ellenhorn JD, Ballantyne GH, Paz IB. Robotic-assisted laparoscopic low anterior resection with total mesorectal excision for rectal cancer. *Surg Endosc.* 2006; 20(10):1521-5.
  8. Antoniou SA, Antoniou GA, Koch OO, et al. Robot-assisted laparoscopic surgery of the colon and rectum. *Surg Endosc.* 2012; 26(1): 1-11.
  9. Collinson FJ, Jayne DG, Pigazzi A, et al. An international, multicentre, prospective, randomised, controlled, unblinded, parallel-group trial of robotic-assisted versus standard laparoscopic surgery for the curative treatment of rectal cancer. *Int J Colorectal Dis.* 2012; 27(2):233-41.
  10. Katsios C, Baltogiannis G. Advances and high demands in totally robotic surgery for rectal cancer. *Surg Endosc.* 201; 25(5): 1691-2.
  11. Karahasanoglu T, Hamzaoglu I, Baca B et al. Robotic surgery for rectal cancer: initial experience from 30 consecutive patients. *J Gastrointest Surg.* 2012; 16(2):401-7.
  12. Park YA, Kim JM, Kim SA, et al. Totally robotic surgery for rectal cancer: from splenic flexure to pelvic floor in one setup. *Surg Endosc.* 2010; 24(3):715-20.
  13. Peterson CY, McLemore EC, Horgan S, et al. Technical aspects of robotic proctectomy. *Surg Laparosc Endosc Percutan Tech.* 2012; 22(3):189-93.
  14. Hellan M, Anderson C, Ellenhorn JD et al. Short-term outcomes after robotic-assisted total mesorectal excision for rectal cancer. *Ann Surg Oncol.* 2007; 14(11):3168-73.
  15. Baik SH, Ko YT, Kang CM, et al. Robotic tumor-specific mesorectal excision of rectal cancer: short-term outcome of a pilot randomized trial. *Surg Endosc.* 2008; 22(7):1601-8.
  16. Baik SH, Kwon HY, Kim JS, et al. Robotic versus laparoscopic low anterior resection of rectal cancer: short-term outcome of a prospective comparative study. *Ann Surg Oncol.* 2009; 16(6):1480-7.
  17. Patriti A, Ceccarelli G, Bartoli A, et al. Short- and Medium-Term Outcome of Robot-Assisted and Traditional Laparoscopic Rectal Resection. *JLS.* 2009; 13(2):176-83.
  18. Park JS, Choi GS, Lim KH, et al. Robotic-assisted versus laparoscopic surgery for low rectal cancer: case-matched analysis of short-term outcomes. *Ann Surg Oncol.* 2010; 17(12):3195-202.
  19. Pigazzi A, Luca F, Patriti A, Multicentric study on robotic tumor-specific mesorectal excision for the treatment of rectal cancer. *Ann Surg Oncol.* 2010; 17(6): 1614-20.
  20. deSouza AL, Prasad LM, Marecik SJ, et al. Total mesorectal excision for rectal cancer: the potential advantage of robotic assistance. *Dis Colon Rectum.* 201; 53(12):1611-7.
  21. Kwak JM, Kim SH, Kim J, et al. Robotic vs laparoscopic resection of rectal cancer: short-term outcomes of a case-control study. *Dis Colon Rectum.* 201; 54(2):151-6.
  22. Baek JH, Pastor C, Pigazzi A. Robotic and laparoscopic total mesorectal excision for rectal cancer: a case-matched study. *Surg Endosc.* 2011; 25(2): 521-5.
  23. Zawadzki M, Velchuru V, Albalawi S, et al. Is hybrid robotic laparoscopic assistance the ideal approach for restorative rectal cancer dissection? *Colorectal Dis.* 2013; 25 Epub ahead of print.
  24. Kang J, Yoon KJ, Min BS, et al. The impact of robotic surgery for mid and low rectal cancer: a case-matched analysis of a 3-arm comparison--open, laparoscopic, and robotic surgery. *Ann Surg.* 2013; 257(1):95-101.



25. Baek SJ, Al-Asari S, Jeong DH, et al. Robotic versus laparoscopic coloanal anastomosis with or without intersphincteric resection for rectal cancer. *Surg Endosc.* 2013; 25. [Epub ahead of print]
26. Stănciulea O, Eftimie M, David L, et al. Robotic surgery for rectal cancer: a single center experience of 100 consecutive cases. *Chirurgia (Bucur).* 2013; 108(2):143-51.
27. Memon S, Heriot AG, Murphy DG, et al. Robotic versus laparoscopic proctectomy for rectal cancer: a meta-analysis. *Ann Surg Oncol.* 2012; 19(7):2095-101.
28. Ortiz-Oshiro E, Sánchez-Egido I, Moreno-Sierra J, et al. Robotic assistance may reduce conversion to open in rectal carcinoma laparoscopic surgery: systematic review and meta-analysis. *Int J Med Robot.* 2012; 8(3):360-70.
29. Kim JC, Yang SS, Jang TY, et al. Open versus robot-assisted sphincter-saving operations in rectal cancer patients: techniques and comparison of outcomes between groups of 100 matched patients. *Int J Med Robot.* 2012; 8(4):468-75.
30. Kang J, Min BS, Park YA, et al. Risk factor analysis of postoperative complications after robotic rectal cancer surgery. *World J Surg.* 2011; 35(11):2555-62.
31. Choi DJ, Kim SH, Lee PJ, et al. Single-stage totally robotic dissection for rectal cancer surgery: technique and short-term outcome in 50 consecutive patients. *Dis Colon Rectum.* 2009; 52(11):1824-30.
32. Bianchi PP, Ceriani C, Locatelli A, et al. Robotic versus laparoscopic total mesorectal excision for rectal cancer: a comparative analysis of oncological safety and short-term outcomes. *Surg Endosc.* 2010; 24(11):2888-94.
33. Leong QM, Son DN, Cho JS, et al. Robot-assisted intersphincteric resection for low rectal cancer: technique and short-term outcome for 29 consecutive patients. *Surg Endosc.* 2011; 25(9):2987-92.
34. Kim NK, Kang J. Optimal Total Mesorectal Excision for Rectal Cancer: the Role of Robotic Surgery from an Expert's View. *J Korean Soc Coloproctol.* 2010; 26(6): 377-87.
35. Wexner SD, Bergamaschi R, Lacy A, et al. The current status of robotic pelvic surgery: results of a multinational interdisciplinary consensus conference. *Surg Endosc.* 2009; 23(2): 438-43.
36. Halabi WJ, Kang CY, Jafari MD, et al. Robotic-assisted Colorectal Surgery in the United States: A Nationwide Analysis of Trends and Outcomes. *World J Surg.* 2013 Apr 6. [Epub ahead of print]
37. Asoglu O, Balik E, Kunduz E, et al. Laparoscopic surgery for rectal cancer: outcomes in 513 patients. *World J Surg.* 2013; 37(4): 883-92.
38. Scarpinata R, Aly EH. Does robotic rectal cancer surgery offer improved early postoperative outcomes? *Dis Colon Rectum.* 2013; 56(2): 253-62.
39. Ahlering TE, Skarecky D, Lee D, Clayman RV. Successful transfer of open surgical skills to a laparoscopic environment using a robotic interface: initial experience with laparoscopic radical prostatectomy. *Urol.* 2003; 170(5): 1738-41.
40. Kim YW, Lee HM, Kim NK, et al. The learning curve for robot-assisted total mesorectal excision for rectal cancer. *Surg Laparosc Endosc Percutan Tech.* 2012; 22(5): 400-5.
41. Jiménez-Rodríguez RM, Díaz-Pavón JM, de la Portilla de Juan F, et al. Learning curve for robotic-assisted laparoscopic rectal cancer surgery. *Int J Colorectal Dis.* 2013; 28(6): 815-21.
42. Wedmid A, Mendoza P, Sharma S, et al. Rectal injury during robot-assisted radical prostatectomy: incidence and management. *J Urol.* 2011; 186(5): 1928-33.
43. Hermsen ED, Hinze T, Sayles H, et al. Incidence of surgical site infection associated with robotic surgery. *Infect Control Hosp Epidemiol.* 2010; 31(8): 822-7.
44. John Carreyou. Surgical robot examined in injuries. available on *The Wall Street Journal.* 2010 May 4.
45. Sohn W, Lee HJ, Ahlering TE. Robotic surgery: review of prostate and bladder cancer. *Cancer J.* 2013; 19(2): 133-9.
46. Liberman D, Trinh QD, Jeldres C, et al. Is robotic surgery cost-effective. *Yes. Curr Opin Urol.* 2012; 22: 61-65.
47. Lotan Y. Is robotic surgery cost-effective. *No. Curr Opin Urol.* 2012; 22: 66-69.
48. Prasad LM, deSouza AL, Marecik SJ. Robotic pursestring technique in low anterior resection. *Dis Colon Rectum.* 2010; 53(2): 230-4.





49. Park IJ, You YN, Schlette E, et al. Reverse-hybrid robotic mesorectal excision for rectal cancer. *Dis Colon Rectum*. 2012; 55(2): 228-33.
50. Choi GS, Park IJ, Kang BM, et al. A novel approach of robotic-assisted anterior resection with transanal or transvaginal retrieval of the specimen for colorectal cancer. *Surg Endosc*. 2009; 23(12): 2831-5.
51. Bae SU, Baek SJ, Hur H, Baik SH, Kim NK, Min BS. Intraoperative near infrared fluorescence imaging in robotic low anterior resection: three case reports. *Yonsei Med J*. 2013, 54(4):1066-9.